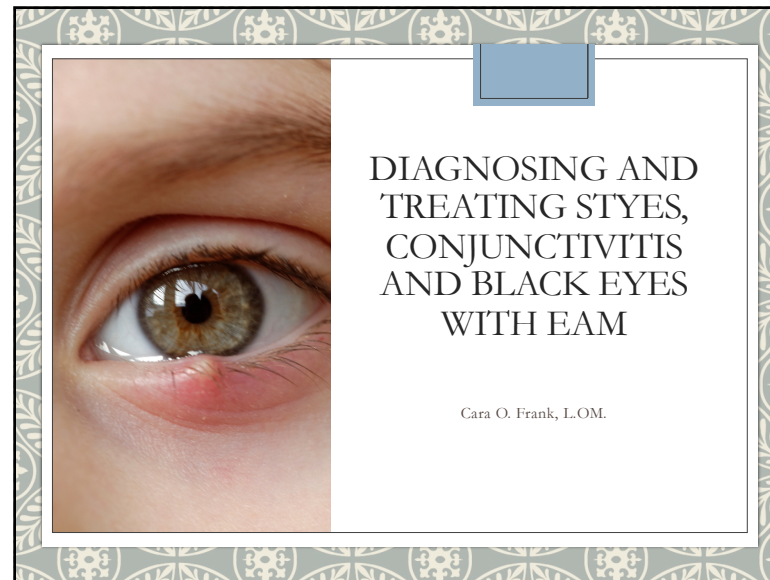





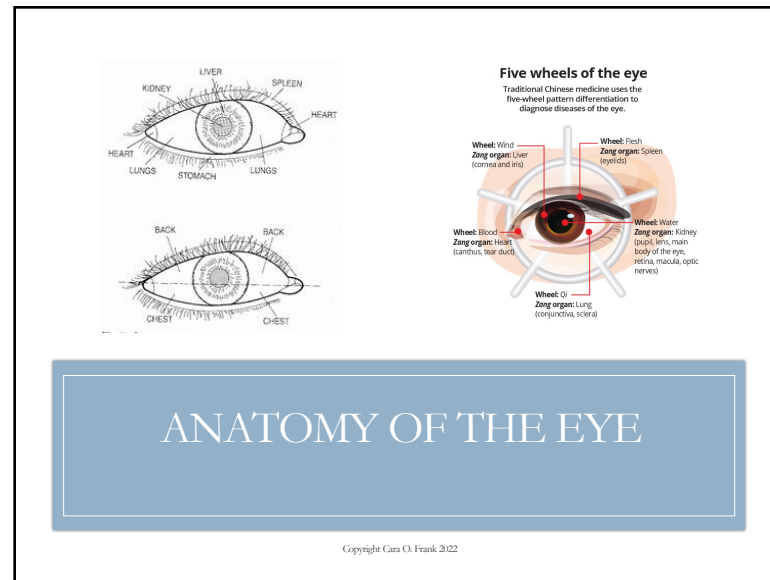
1



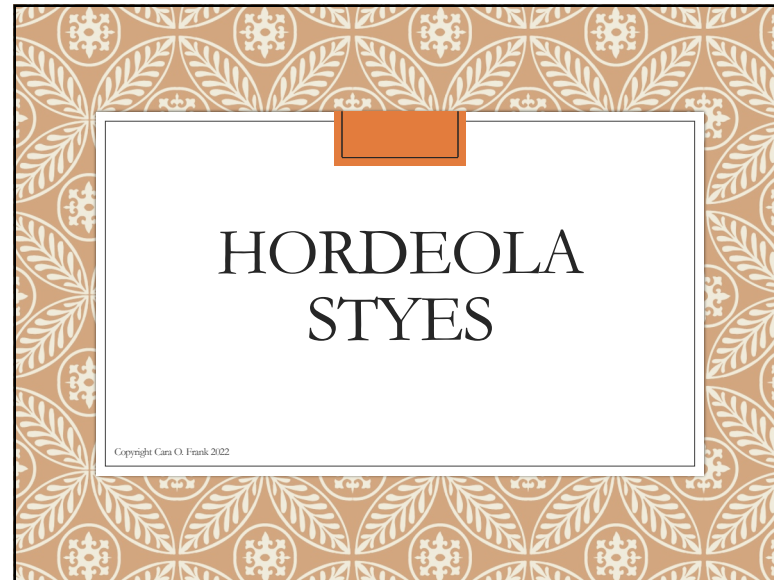2



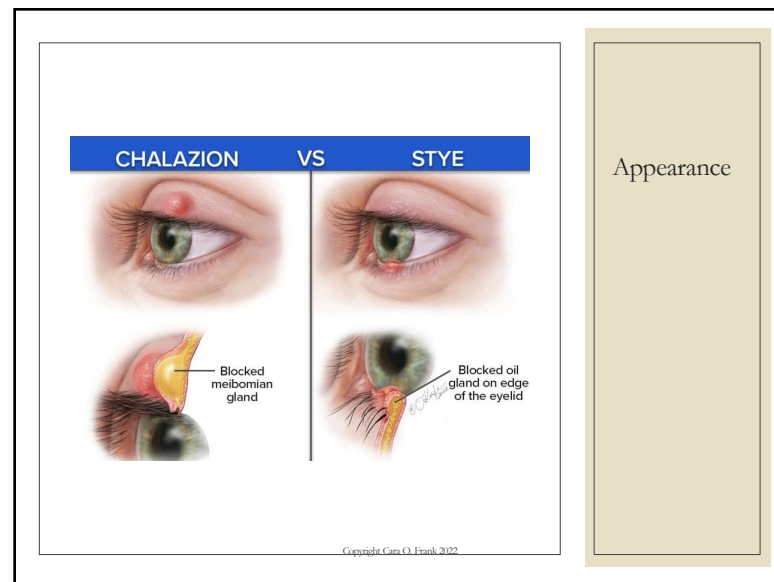
3



4



5



6

What's the diff between Styes and Chalazia?

- A **hordeolum (or a stye)** is a localized inflammation and/or infection of the hair follicles of the eyelid or the meibomian glands.
- usually acute, can be recurrent.
- Can be painful with erythema and edematous.
- 90-95% of cases, *Staphylococcus aureus* is the cause.
- Treatment is mainly with warm compresses (four x day)
- incision to aid drainage is needed.
- Topical antibiotics for recurrent or actively draining hordeola. Ophthalmologic consultation is recommended if not improving in 2-3 days.
- <https://pediatriceducation.org/2010/07/05/whats-the-difference-between-a-stye-hordeolum-and-chalazion/>
- A chalazion is a swelling caused by blockage of sebaceous glands and formation of granulomas.
- It usually occurs in the meibomian glands in the tarsal plates, but also can occur in the sebaceous glands of Zeis.
- Is chronic and usually painless.
- Internal hordeola may lead to chalazia. Chalazia can become quite large and put pressure on the cornea and thereby cause visual changes.
- Chalazia usually are treated with warm compresses (4 times/day). Washing the eyelashes with a baby shampoo may also help with lid hygiene and improves control of seborrheic dermatitis if present.

Copyright Cara O. Frank, 2022

7

Hordeola and Chalazia Terminology

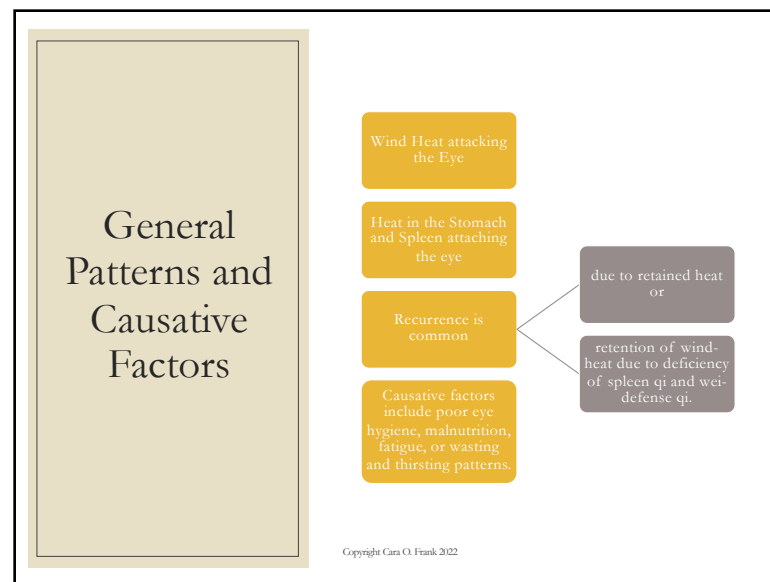
针眼 stye *zhēn yǎn*

麦粒肿 Hordeolum Wheat Grain Swelling *Mài Lì Zhǒng*

胞生痰核 phlegm node in eyelid (chalazion)
bāo shēng tán hé

Copyright Cara O. Frank, 2022

8



9

金银花	<i>jīn yīn huā</i>	30g	Flos Lonicerae Japonicae
连翘	<i>lián qiào</i>	15g	Fructus Forsythiae
荆芥	<i>jīng jiè</i>	9g	Herba Schizonepetae
薄荷	<i>bò hé</i>	9g	Herba Menthae
桔梗	<i>jié gěng</i>	9g	Radix Platycodonis
牛蒡子	<i>niú bàng zǐ</i>	15g	Fructus Arctii
赤芍	<i>chì sháo</i>	9g	Radix Paconiae Rubra
白芷	<i>bái zhǐ</i>	6g	Radix Angelicae Dahuricae
黄芩	<i>huáng qín</i>	9g	Radix Scutellariae
野菊花	<i>yě jú huā</i>	9g	Flos Chrysanthemi Indici
甘草	<i>gān cǎo</i>	6g	Radix et Rhizoma Glycyrrhizae

Wind Heat Attacking the Eye
Modified *Yin Qiao San* (Lonicera and Forsythia Powder)

- Foreign body sensation in the eye.
- Photophobia
- Mild Pain, redness and swelling
- Poss. Low grade fever and headache
- Tx Pr: Dispel Wind, Clear Heat, Cool Blood

Copyright Cara O. Frank, 2022

10

木香	<i>mu xiang</i>	6g	Radix Aucklandiae
黃連	<i>huang lian</i>	9g	Rhizoma Coptidis
梔子	<i>zhi zi</i>	9g	Fructus Gardeniae
赤芍	<i>chi shao</i>	9g	Radix Paeoniae Rubra
黃芩	<i>huang qin</i>	9g	Radix Scutellariae
白芷	<i>bai zhi</i>	6g	Radix Angelica Dahuricae
乳香	<i>ru xiang</i>	6g	Olibanum
天花粉	<i>tian hua fen</i>	6g	Radix Trichosanthis
薄荷	<i>bo he</i>	9g	Herba Mentha
玄參	<i>xuan shen</i>	6g	Radix Scrophulariae
桔梗	<i>ji geng</i>	9g	Radix Platycodi
連翹	<i>lian qiao</i>	15g	Fructus Forsythiae
甘草	<i>gan cao</i>	12g	Radix Glycyrrhizae
大黃	<i>da huang</i>	6g	Radix et Rhizoma Rhei

Copyright Cara O. Frank, 2022

Fire Toxin
 Nèi shū huáng lián tāng
 Modified Interior Expelling Coptis
 Decoction

- Severe. Swelling and redness. Mass is large and painful. Poss. pustulation.
- Tender lymph nodes around ear or neck.
- Headache, fever, thirst for cold. Dry stool.
- Red tongue, yellow coating.
- Tx Pr: clear heat, cool blood, dissipate masses

11

Case Study

- Male, age 9. Initial Visit: September 15, 2008.
- **Chief Complaint:** Redness, swelling and tenderness of the upper right eyelid for 5 days.
- **History:** Approximately 1 year prior to treatment, the patient frequently experienced redness, swelling and pain in his right eye. The same symptoms appeared again 5 days prior to the first visit. Several hospitals diagnosed him with an external hordeolum of the right eye. During the previous year, the patient received three drainage surgeries after which the localized redness and swelling would gradually be reduced. The patient had frequent recurrences.
- **Signs and Symptoms:** Localized redness and swelling close to the margin of the upper right eyelid with palpable induration and tenderness with no pus formation. The patient was a picky eater with a poor appetite, dry mouth, pale complexion, hard stools and frequent colds. The tongue body was tender with a thin sticky yellowish coating; his pulse was thin and rapid.
- **Past History:** Frequent upper respiratory infections.

Copyright Cara O. Frank, 2022

12

黄芪	<i>huáng qí</i>	15g	Radix Astragali
茯苓	<i>fú líng</i>	10g	Poria
白术	<i>bái zhú</i>	10g	Rhizoma Atractylodis Macrocephalae
陈皮	<i>chén pí</i>	6g	Pericarpium Citri Reticulatae
赤芍	<i>chì sháo</i>	10g	Radix Paeoniae Rubra
薏苡仁	<i>yì yī rén</i>	20g	Semen Coicis
桔梗	<i>jié gēng</i>	10g	Radix Platycodonis
皂角刺	<i>zǎo jiǎo cì</i>	6g	Spina Gleditsiae
连翘	<i>lián qiào</i>	15g	Fructus Forsythiae
金银花	<i>jīn yín huā</i>	15g	Flos Lonicerae Japonicae
蒲公英	<i>pú gōng yīng</i>	15g	Herba Taraxaci
莱菔子	<i>lái fú zǐ</i>	15g	Semen Raphani

Copyright Cara O. Frank, 2022

Formula: Modified *Tūo Lǐ Xiào Dú Sǎn* (Interior-Drawing and Toxin-Removing Powder)
[托里消毒散]

- *Huang qi* tonifies the yang qi of the spleen and stomach to ascend and disperse pathogenic factors. It is combined with *bái zhú*, *fú líng*, *yì yī rén* and *gan cao* to supplement qi and strengthen the spleen.
- *Chén pí* regulates qi, clears obstruction and relieves qi stagnation.
- *Lái fú zǐ* regulates qi to resolve food stagnation.
- *Jié gēng* circulates the lung qi, opening and regulating the waterways. While nourishing Earth and generating Metal, it guides the effects of the other medicinals upward.
- *Chì sháo* cools the blood and dissipates redness.
- *Lián qiào*, *jīn yín huā* and *pú gōng yīng* clear heat and toxic fire to treat the superficial excessive manifestations, while also draining accumulated heat.

13

Follow up:

Formula:
Modified *Shēn Líng Bái Zhú Sǎn* (Ginseng, Poria and Atractylodes Macrocephalae Powder)
[参苓白术散]

太子参	<i>tài zǐ shēn</i>	15g	Radix Pseudostellariae
茯苓	<i>fú líng</i>	10g	Poria
白术	<i>bái zhú</i>	10g	Rhizoma Atractylodis Macrocephalae
山药	<i>shān yào</i>	20g	Rhizoma Dioscoreae
陈皮	<i>chén pí</i>	6g	Pericarpium Citri Reticulatae
扁豆	<i>biǎn dòu</i>	15g	Semen Lablab Album
桔梗	<i>jié gēng</i>	10g	Radix Platycodonis
炙甘草	<i>zhì gān cǎo</i>	5g	Radix et Rhizoma Glycyrrhizae Praeparata cum Melle
薏苡仁	<i>yì yī rén</i>	20g	Semen Coicis
防风	<i>fáng fēng</i>	10g	Radix Saposhnikovia
赤芍	<i>chì sháo</i>	10g	Radix Paeoniae Rubra
连翘	<i>lián qiào</i>	15g	Fructus Forsythiae

Copyright Cara O. Frank, 2022

14

Mini Case

- A patient presented with **recurrent hordeola** with limited redness and swelling of the right eyelid close to the lid margin.
- There was a small induration, a yellowish complexion and fatigue. The tongue was pale with a white and slightly sticky coating. The pulse was thin and rapid.
- *Liù Jūn Zǐ Tāng* (Six Gentlemen Decoction) plus *pú gōng yīng* and *zào jiǎo*

Copyright Cara O. Frank 2022

15

BACTERIAL CONJUNCTIVITIS

Copyright Cara O. Frank 2022

16

- Contact lens wearers
- Common colds
- Sinusitis
- Immunodeficiency
- Exposure to STD's at birth


Conjunctivitis Risk Factors

Copyright Cara O. Frank, 2022

17

3 primary types/2 related types

- Acute
- Chronic
- Vernal keratoconjunctivitis
- Epidemic Hemorrhagic
- Phlyctenular keratoconjunctivitis



Copyright Cara O. Frank, 2022

18

Acute
Contagious
Conjunctivitis

- Refers to inflammation of the conjunctiva by bacteria
- Three stages: hyperacute, acute and chronic
- Called Pink Eye
- Usually caused by strep or staph infections

Copyright Cara O. Frank 2022

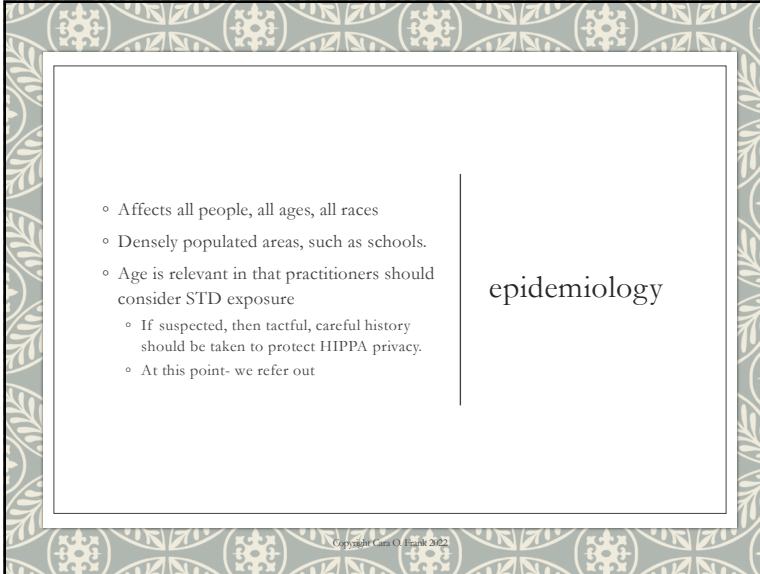
19

Acute
Contagious
Conjunctivitis

- Usually begins in one eye
- Can spread to the other eye
- Usually most severe on days 3-4
- Can resolve within 1-2 weeks
- Highly contagious and can become epidemic
- Leading cause of school absences

Copyright Cara O. Frank 2022

20

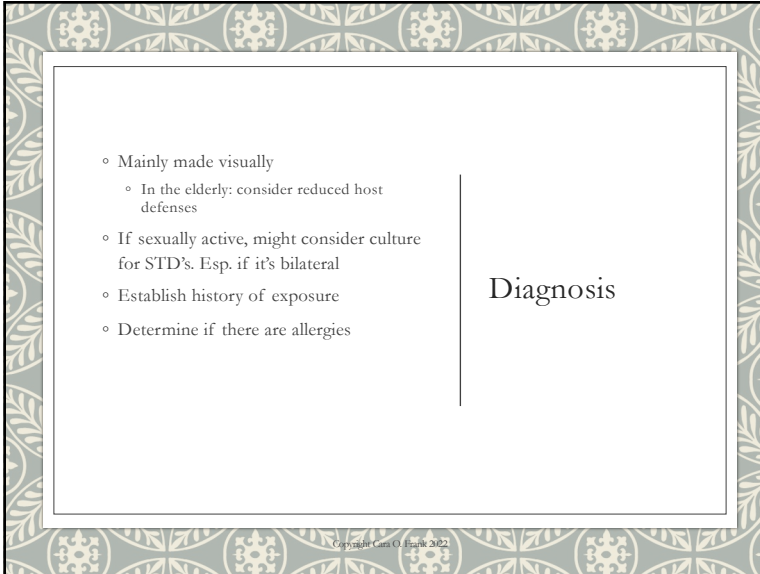


- Affects all people, all ages, all races
- Densely populated areas, such as schools.
- Age is relevant in that practitioners should consider STD exposure
 - If suspected, then tactful, careful history should be taken to protect HIPPA privacy.
 - At this point- we refer out

epidemiology

Copyright Cara O. Frank 2022

21



- Mainly made visually
 - In the elderly: consider reduced host defenses
- If sexually active, might consider culture for STD's. Esp. if it's bilateral
- Establish history of exposure
- Determine if there are allergies

Diagnosis

Copyright Cara O. Frank 2022

22

Visual Diagnosis

- Discharge will be more purulent than with viral conjunctivitis
- Lids will appear mucousy, which can be white, green or yellow
- Eyelids may be edematous
- The pupil should respond normally
- There should not be tearing

Copyright Cara O. Frank 2022


23

- Generally prognosis is excellent
- Antibiotic drops and ointments form the backbone of al treatments:
 - Trimethoprim with polymixin B
 - Gentamicin
 - Tobramycin
 - Neomycin
 - Ciprofloxacin
 - Ofloxacin
 - Gatifloxacin
 - Erythromycin

Prognosis and Western medical treatment

Copyright Cara O. Frank 2022

24



Prognosis and Western medical treatment

If the cornea can't be visualized, refer to western doctor

A serious complication of a Chlamydia infection is Trachoma:

- Trachoma is a disease of the eye caused by infection with the bacterium *Chlamydia trachomatis*. It is a public health problem in 42 countries, and is responsible for the blindness or visual impairment of about 1.9 million people. Blindness from trachoma is irreversible.
- 椒疮 prickly-ash-like sore (trachoma)
[jiāo chuāng]

Copyright Cara O. Frank 2022

25

◦ *Bào Fēng Kè Rè*

◦ 暴风客热

◦ Fulminant wind and invading fever

TCM Terminology

Copyright Cara O. Frank 2022

26

Presentation and Cause


Abrupt onset,
conjunctival redness,
burning and itching,
tearing, sticky discharge,
and pain.

The eyelids and the
conjunctiva are red and
swollen.


Copyright Cara O. Frank, 2022

27

Presentation and Cause



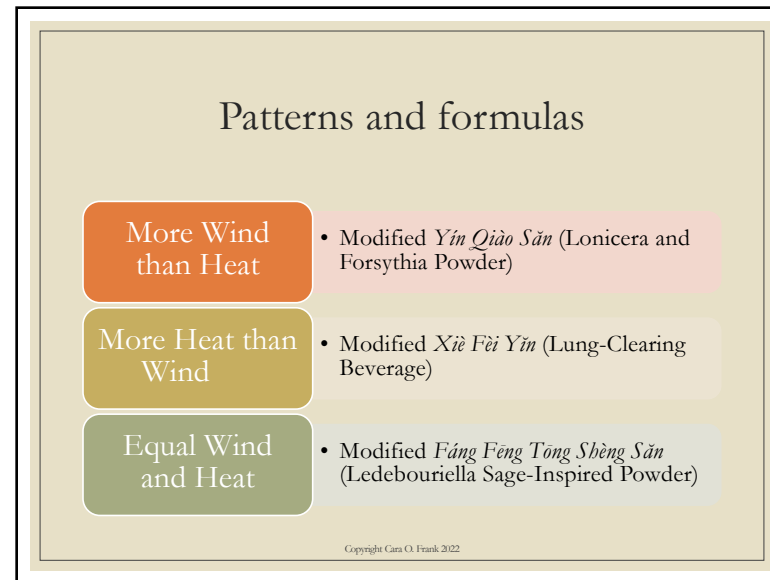
All patterns center on Pathogenic wind and heat which contend with each other, stagnate in the lung, and then attack upward to affect the conjunctiva.



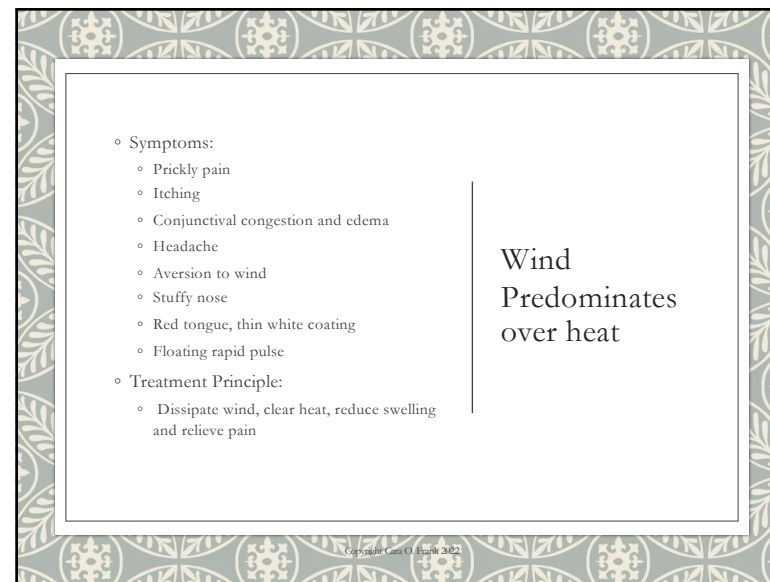
It is primarily caused by externally contracted wind-heat and/or constrained heat in the interior.

Copyright Cara O. Frank, 2022

28



29



30

Modified Yin Qiao San

金银花	<i>jīn yīn huā</i>	25g	Flos <i>Lonicerae Japonicae</i>
连翘	<i>lián qiào</i>	25g	Fructus <i>Forsythiae</i>
桔梗	<i>jié gēng</i>	10g	Radix <i>Platycodonis</i>
薄荷	<i>bó hé</i>	10g	Herba <i>Menthae</i>
荆芥	<i>jīng jiè</i>	10g	Herba <i>Schizonepetae</i>
牛蒡子	<i>niú bàng zǐ</i>	15g	Fructus <i>Arctii</i>
竹叶	<i>zhú yè</i>	10g	Folium <i>Phyllostachidis Henonis</i>
芦根	<i>lú gēn</i>	20g	Rhizoma <i>Phragmitis</i>
牡丹皮	<i>mǔ dān pí</i>	15g	Cortex <i>Moutan</i>
赤芍	<i>chì sháo</i>	15g	Radix <i>Paeoniae Rubra</i>
生甘草	<i>shēng gān cǎo</i>	5g	Radix et Rhizoma <i>Glycyrrhizae</i> (raw)

Copyright Cara O. Frank 2022

31

- Symptoms
 - Increased pain
 - Profuse sticky discharge
 - Hot tears
 - Red swollen eyelids
 - Red conjunctiva
 - Aversion to heat
 - Thirst with desire to drink
 - Dry stools and yellow urine
 - Red tongue with yellow coating
 - Rapid pulse
- Treatment Principle:
 - Clear heat, eliminate toxins, dissipate wind and relieve pain

Heat overacting
on wind

Copyright Cara O. Frank 2022

32

Modified <i>Xiè Fèi Yǐn</i> (Lung-Draining Beverage)			
石膏	<i>shí gāo</i>	10 g	Gypsum Fibrosum
赤芍	<i>chì sháo</i>	10 g	Radix Paeoniae Rubra
黄芩	<i>huáng qín</i>	3 g	Radix Scutellariae
桑白皮	<i>sāng bái pí</i>	10 g	Cortex Mori
枳壳	<i>zhǐ qiào</i>	10 g	Fructus Aurantii
木通	<i>mù tōng</i>	10 g	Caulis Akebiae
连翘	<i>lián qiào</i>	10 g	Fructus Forsythiae
荆芥	<i>jīng jiè</i>	10 g	Herba Schizonepetae
防风	<i>fáng fēng</i>	10 g	Radix Saposhnikoviae
梔子	<i>zhī zǐ</i>	10 g	Fructus Arctii
白芷	<i>bái zhǐ</i>	10 g	Radix Angelicae Dahuricae
羌活	<i>qiāng huó</i>	10 g	Rhizoma et Radix Notopterygii
甘草	<i>gān cǎo</i>	3 g	Radix et Rhizoma Glycyrrhizae

Copyright Cara O. Frank 2022

33

<ul style="list-style-type: none"> ◦ Marked conjunctival congestion and edema: <ul style="list-style-type: none"> ◦ <i>jié gēng</i> (Radix Platycodonis) 10g ◦ <i>tíng lì zǐ</i> (Semen Lepidii) 10g ◦ <i>shèng dī</i> (Radix Rehmanniae) 10g ◦ <i>mǔ dān pí</i> (Cortex Moutan) 10g ◦ Constipation: <ul style="list-style-type: none"> ◦ <i>dà huáng</i> (Radix et Rhizoma Rhei) 10g. 	Modifications:
---	----------------

Copyright Cara O. Frank 2022

34

Equal Wind and Heat

- Falls into an interior/ exterior excess pattern
 - Burning pain, Itching
 - Fever and aversion to cold
 - Photophobia
 - Conjunctival redness and edema
 - Hot tears
 - Thirst
 - Dark urine and dry stool
 - Red tongue white coating, Thready rapid pulse or wiry and thready
- Treatment Principle:
 - Clear Heat, remove toxins, dissipate wind and expel the pathogen

Copyright Cara O. Frank 2022

35

Fáng Fēng Tōng Shèng Sǎn (防 风通圣散, Ledebouriella Sage-Inspired Powder)

防风	<i>fáng fēng</i>	15g	Radix Saposhnikoviae
川芎	<i>chuān xiōng</i>	15g	Rhizoma Chuanxiong
大黄	<i>dà huáng</i>	15g	Radix et Rhizoma Rhei
赤芍	<i>chì sháo</i>	15g	Radix Paeoniae Rubra (usually 'bai shao')
连翘	<i>lián qiào</i>	15g	Fructus Forsythiae
麻黄	<i>má huáng</i>	15g	Herba Ephedrae
芒硝	<i>máng xiāo</i>	15g	Natrii Sulfas
薄荷	<i>bò he</i>	15g	Herba Menthae
当归	<i>dāng guī wēi</i>	15g	Radix Angelicae Sinensis extremities
滑石	<i>huá shí</i>	60g	Talcum
甘草	<i>gān cǎo</i>	60g	Herba Schizonepetae
炒栀子	<i>chǎo zhī zǐ</i>	15g	dry-fried Fructus Gardeniae
白术	<i>bái zhú</i>	15g	Rhizoma Atractylodis Macrocephalae
桔梗	<i>jié gēng</i>	30g	Rhizoma Phragmitis
石膏	<i>shí gāo</i>	30g	Gypsum Fibrosum
荆芥穗	<i>jīng jiè suì</i>	15g	Spica Schizonepetae
黄芩	<i>huáng qín</i>	30g	Radix Scutellariae

Copyright Cara O. Frank 2022

36

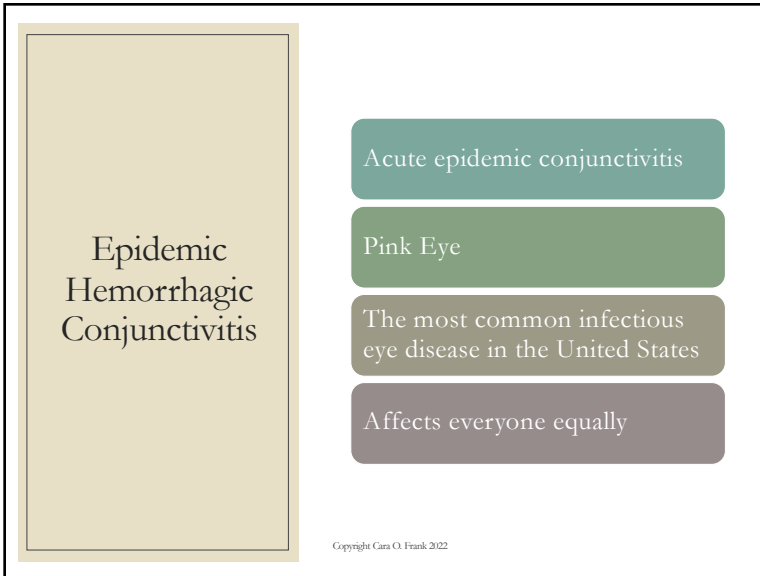


- **Eye drops:**
 - 0.5% bear bile eye drops, 6 times per day.
 - Antibiotic eye drops
- **Eye wash methods:**
 - Decoct *pú gōng yīng* (Herba Taraxaci) 30g, *yě jú huā* (Flos Chrysanthemi Indici) 30g and *huáng lián* (Rhizoma Coptidis) 10g and other heat-clearing and toxin-resolving herbs to fumigate and steam the affected eye, 2-3 times per day.

External therapies

Copyright Cara O. Frank 2022

37



Epidemic Hemorrhagic Conjunctivitis

- Acute epidemic conjunctivitis
- Pink Eye
- The most common infectious eye disease in the United States
- Affects everyone equally

Copyright Cara O. Frank 2022

38

Epidemic Hemorrhagic Conjunctivitis

- Usually presents bilaterally and affects both eyes within 24 hours
- Usually the presentation is enough to make the diagnosis.
- can be cultured for *staphylococcus epidermidis*, *streptococcus pyogenes*, or *streptococcus pneumoniae*, or STD's

Copyright Cara O. Frank, 2022

39

Epidemic Hemorrhagic Conjunctivitis

- comfort measures:
 - such as cold compresses
 - artificial tears
 - antibiotics.
 - It is extremely important to avoid contamination by careful and frequent hand washing.
 - The prognosis is good, but frequently reoccurs.

Copyright Cara O. Frank, 2022

40

TCM:
Tiān xíng chì yǎn
 (heaven-current red eye)

dry, burning, painful sensation in the affected eye

copious tearing-watery, bit pus filled

redness and swelling of the lid and the sclera with numerous millet-like sores in the palpebrae conjunctiva.

Later, blood spillage may spread to the entire sclera with a star nebula in the pupil.

There may be palpable nodules anterior to the ear or below the jaw.

occurs rapidly with a short incubation period and is highly contagious. It usually affects both eyes within 24 hrs. and is often epidemic, but with a good prognosis.

Copyright Cara O. Frank 2022

41

Acute
 Contagious
 Conjunctivitis
 TCM Patterns
 and Formulas

Early-stage epidemic pestilential qi invasion

- Modified *Qū Fēng Sān Rè Yǐn Zī* (Wind-Expelling and Heat-Dissipating Drink)

Accumulated heat in the lung and stomach

- Pǔ Jì Xiǎo Dú Yǐn* (Universal Relief Toxin-Removing Beverage)

Epidemic heat damaging collaterals:

- Modified *Xiè Fèi Yǐn* (Lung-Draining Beverage)

Copyright Cara O. Frank 2022

42

Modified *Qū Fēng Sàn Rè Yǐn Zǐ* (Wind-Expelling and Heat-Dissipating Drink)

连翘	<i>lián qiào</i>	Fructus Forsythiae
金银花	<i>jīn yín huā</i>	Flos Lonicerae Japonicae
牛蒡子	<i>niú bàng zǐ</i>	Fructus Arctii
薄荷	<i>bò he</i>	Herba Menthae
梔子	<i>zhī zǐ</i>	Fructus Gardeniae
羌活	<i>qiāng huó</i>	Rhizoma et Radix Notopterygii
大黄	<i>dà huáng</i>	Radix et Rhizoma Rhei
赤芍	<i>chì sháo</i>	Radix Paeoniae Rubra
当归	<i>dāng guī</i>	Radix Angelicae Sinensis
川芎	<i>chuān xiōng</i>	Rhizoma Chuanxiong
木贼	<i>mù zéi</i>	Herba Equiseti Hiemalis

Copyright Cara O. Frank, 2022

43

Pǔ Jì Xiǎo Dú Yǐn (普济消毒饮, Universal Relief Toxin-Removing Beverage)

黄连	<i>huáng lián</i>	15 g	Rhizoma Coptidis
黄芩	<i>huáng qín</i>	15 g	Radix Scutellariae
陈皮	<i>chén pí</i>	6 g	Pericarpium Citri Reticulatae
甘草	<i>gān cǎo</i>	6 g	Herba Schizonepetae
玄参	<i>xuán shēn</i>	6 g	Radix Scrophulariae
柴胡	<i>chái hú</i>	6 g	Radix Bupleuri
桔梗	<i>jié gēng</i>	6 g	Rhizoma Phragmitis
连翘	<i>lián qiào</i>	3 g	Fructus Forsythiae
板蓝根	<i>bǎn lán gēn</i>	3 g	Radix Isatidis
马勃	<i>mǎ bó</i>	3 g	Lasiosphaera seu Calvatia
牛蒡子	<i>niú bàng zǐ</i>	3 g	Fructus Arctii
薄荷	<i>bò he</i>	3 g g	Herba Menthae
僵蚕	<i>jiāng cān</i>	2.1 g	Bombyx Batryticatus
升麻	<i>shēng má</i>	2.1 g	Rhizoma Cimicifugae

Copyright Cara O. Frank, 2022

44

- **Eye drops:** 0.2% Heartleaf Houlttuynia Medicinal Eye Drops, 6 times per day, or once every hour for severe cases. It may also use antiviral eye drops combined with antibiotic eye drops.
- **Eye wash methods:** Decoct *dà qīng yè* (Folium Isatidis) 20g, *jīn yīn huā* (Flos Lonicerae Japonicae) 15g, *pú gōng yīng* (Herba Taraxaci) 30g, *jú huā* (Flos Chrysanthemi) 15g and other heat-clearing and toxin-resolving herbs to fumigate and wash the affected eye, 2-3 times per day.

External Therapy

Copyright Cara O. Frank 2022

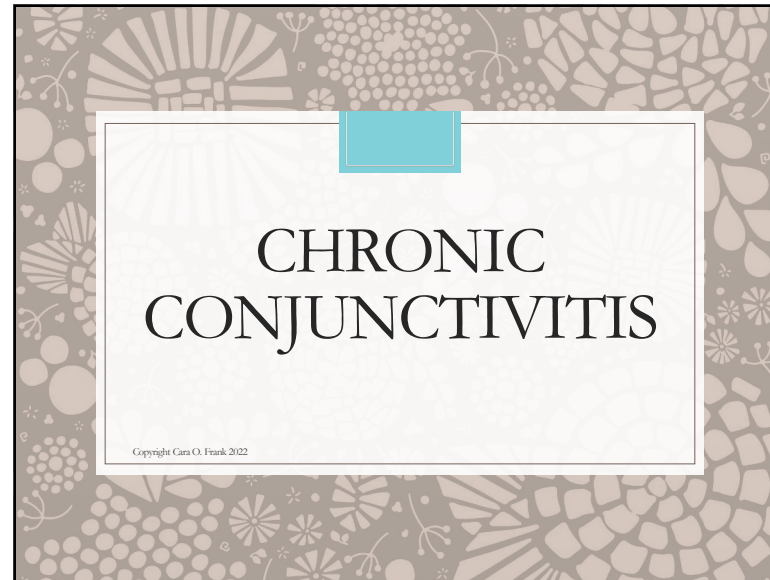
45

Modified *Xī Jiǎo Dì Huāng Tāng* (Rhinoceros Horn and Rehmannia Decoction) and *Yīn Qiào Sǎn* (Lonicera and Forsythia Powder)

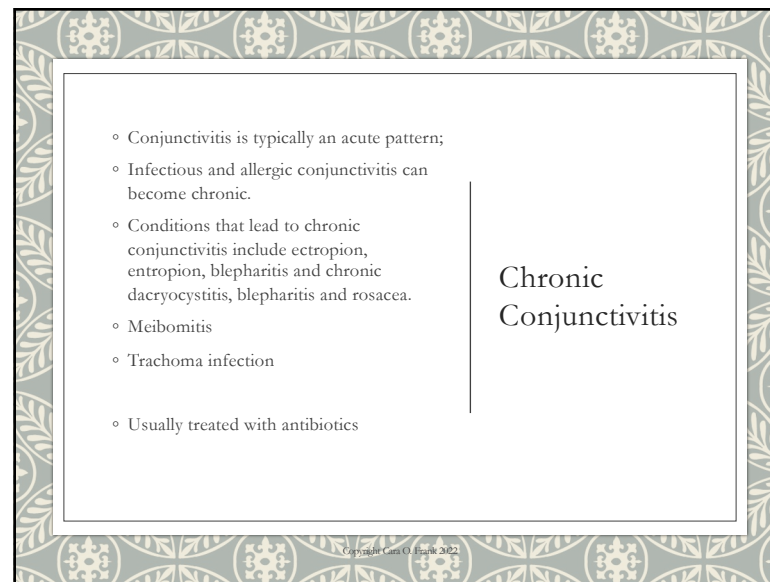
水牛角	<i>shuǐ niú jiǎo</i>	40g	Cornu Bubali (decocted first for 30 min)
牡丹皮	<i>mǔ dān pí</i>	15g	Cortex Moutan
赤芍	<i>chì sháo</i>	15g	Radix Paeoniae Rubra
生地黄	<i>shēng dì huāng</i>	15g	Radix Rehmanniae
紫草	<i>zǐ cǎo</i>	5g	Radix Arnebiae
金银花	<i>jīn yīn huā</i>	25g	Flos Lonicerae Japonicae
连翘	<i>lián qiào</i>	25g	Fructus Forsythiae
薄荷	<i>bò hē</i>	10g	Herba Menthae
荆芥	<i>jīng jiè</i>	10g	Herba Schizonepetae
竹叶	<i>zhú yè</i>	10g	Folium Phyllostachydis Henonis
芦根	<i>lú gēn</i>	20g	Rhizoma Phragmitis
生甘草	<i>shēng gān cǎo</i>	5g	Radix et Rhizoma Glycyrrhizae

Copyright Cara O. Frank 2022

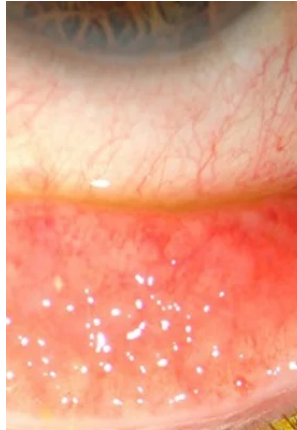
46



47



48



Chronic Conjunctivitis TCM
Bái sè zhèng (white dry eye or white xerotic syndrome).

- It is characterized by mild redness or thin red veins in the sclera with dryness and discomfort.

Copyright Cara O. Frank 2022

49

- Causes:
 - Incomplete treatment of fulminant wind with an invading fever
 - part of the sequelae of acute contagious conjunctivitis where there is lingering heat hidden in the sclera
 - Other factors include poor diet, excessive smoking or drinking alcohol and excessive consumption of spicy-hot food.

bái sè zhèng
white dry eye
or white xerotic
syndrome

Copyright Cara O. Frank 2022

50



- Pathogenesis
 - lifestyle habits cause damp-heat accumulation in the spleen and stomach with inhibited qi movement, resulting in pathogenic stagnation in the sclera.
 - Other possible causative factors include a lack of nourishment to the eyes due to lung yin deficiency and fluid loss, liver and kidney deficiency or yin and blood deficiency resulting in a lack of fluid and tears, all of which result in malnourishment of the sclera.

bái sè zhèng
white dry eye
or white xerotic
syndrome

Copyright Cara O. Frank 2022

51

COMMON CLINICAL PATTERNS AND FORMULAS

Lingering evil heat

- Modified *Sāng Bái Pí Tāng* (Mulberry Root Bark Decoction)

Lung yin deficiency

- Modified *Yāng Yīn Qīng Fèi Tāng* (Yin-Nourishing and Lung-Clearing Decoction)

Spleen and stomach damp-heat

- Modified *Sān Rén Tāng* (Three Kernels Decoction)

Liver and kidney yin deficiency

- Modified *Qǐ Jù Dì Huáng Wǎn* (Lycium Berry, Chrysanthemum and Rehmannia Pill)

Copyright Cara O. Frank 2022

52

Lingering Evil Heat

Formula: Modified *Sāng Bái Pí Tāng* (Mulberry Root Bark Decoction)

桑白皮	<i>sāng bái pí</i>	10g	Cortex Mori
玄参	<i>xuán shēn</i>	15g	Radix Scrophulariae
地骨皮	<i>dì gǔ pí</i>	10g	Cortex Lycii
麦冬	<i>mài dòng</i>	15g	Radix Ophiopogonis
黄芩	<i>huáng qín</i>	10g	Radix Scutellariae
菊花	<i>jú huā</i>	10g	Flos Chrysanthemi
生地黄	<i>shēng dì huáng</i>	15g	Radix Rehmanniae
桔梗	<i>jié gěng</i>	6g	Radix Platycodonis
茯苓	<i>fú líng</i>	10g	Poria
甘草	<i>gān cǎo</i>	3g	Radix et Rhizoma Glycyrrhizae

Copyright Cara O. Frank, 2022

53

Lung Yin Deficiency

Modified *Yāng Yīn Qīng Fèi Tāng* (Yin-Nourishing and Lung-Clearing Decoction).

<i>shēng dì</i>	生地	Radix Rehmanniae
<i>xuán shēn</i>	玄参	Radix Scrophulariae
<i>mù dan pí</i>	牡丹皮	Cortex Moutan
<i>bái sháo</i>	白芍	Radix Paeoniae Alba
<i>mài mén dòng</i>	麦门冬	Radix Ophiopogonis
<i>bò he</i>	薄荷	Herba Menthae
<i>chuān bèi mǔ</i>	川贝母	Bulbus Fritillariae Cirrhosae
<i>gān cǎo</i>	甘草	Radix et Rhizoma Glycyrrhizae

Copyright Cara O. Frank, 2022

54

Spleen and Stomach Damp-Heat *Sān Rén Tāng* (三仁汤, Three Kernels Decoction)

b	<i>xīng rén</i>	15 g	Semen Armeniacae Amarum
滑石	<i>huá shí</i>	18 g g	Talcum
白通草	<i>bái tōng cǎo</i>	6 g	Medulla Tetrapanacis
白豆蔻	<i>bái dòu kǒu</i>	6 g	Fructus Amomi Kravanh
竹叶	<i>zhú yè</i>	6 g	Folium Phyllostachydis Henonis
厚朴	<i>hòu pò</i>	6 g	Cortex Magnoliae Officinalis
薏苡仁	<i>yì yī rén</i>	18 g	Semen Coicis
半夏	<i>bàn xià</i>	15 g	Rhizoma Pinelliae

Copyright Cara O. Frank, 2022

55

Liver and Kidney Yin deficiency *Qǐ Jǔ Dì Huáng Wán* (杞菊地黄丸, Lycium Berry, Chrysanthemum and Rehmannia)

熟地黄	<i>shú dì huáng</i>	Radix Rehmanniae Praeparata
山茱萸	<i>shān zhū yú</i>	Fructus Corni
干山药	<i>gān shān yào</i>	Rhizoma Dioscoreae
泽泻	<i>zé xiè</i>	Rhizoma Alismatis
茯苓	<i>fú líng</i>	Poria
牡丹皮	<i>mǔ dān pí</i>	Cortex Moutan
枸杞子	<i>gǒu qǐ zǐ</i>	Fructus Lycii
菊花	<i>jú huā</i>	Flos Chrysanthemi

Copyright Cara O. Frank, 2022

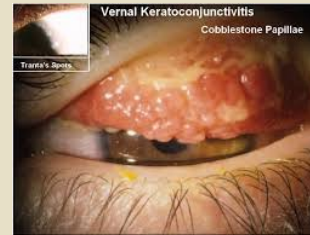56

Vernal Keratoconjunctivitis seasonal conjunctivitis or spring catarrh

intense itching eyes

large cobblestone papillae

brown or dull red jelly-like
thickening bulbar
conjunctiva



Copyright Cara O. Frank, 2022

57

VCK Western Medicine

- Try to identify and avoid the allergens that cause symptoms.
- Topical corticosteroid (0.1% Dexamethasone Eye Drop),
- Angiotonics (0.1% Epinephrine or 1% Ephedrine) is helpful to alleviate itching and redness.
- Ketorolac Tromethamine 0.5%, or Emedastine Difumarate 0.05%, or Nedocromil sodium 2% can reduce the symptoms markedly.
- For severe patients, Chlorphenamine, Astemizole, antihistaminic's or Glucocorticoid

Copyright Cara O. Frank, 2022

58

External contraction of wind-heat

- Modified *Xiao Feng San* (Wind-Dispersing Powder)

Damp-heat

- Modified *Chu Shi Tang* (Dampness Eliminating Decoction)

Blood deficiency generating wind

- Modified *Si Wu Tang* (Four Substances Decoction)

Spleen deficiency with dampness

- Modified *Shen Ling Bai Zhu San* (Ginseng, Poria and Atractylodes Macrocephalae Powder)

Copyright Cara O. Frank, 2022

Vernal Kerato-conjunctivitis

shí fù mù yǎng
时复目痒
seasonal eye itching

59

Modified *Xiao Feng San* (Wind dispersing powder, 消风散)

荆芥穗	<i>jīng jiè suì</i>	10 g	Spica Schizonepetae
羌活	<i>qiāng huó</i>	10 g	Rhizoma et Radix Notopterygii
防风	<i>fáng fēng</i>	10 g	Radix Saposhnikoviae
川芎	<i>chuān xiōng</i>	10 g	Rhizoma Chuanxiong
白僵蚕	<i>bái jiāng cān</i>	10 g	Bombyx Batryticatus
蝉蜕	<i>chán tuì</i>	10 g	Periostracum Cicadae
茯苓	<i>fú líng</i>	10 g	Poria
陈皮	<i>chén pí</i>	10 g	Pericarpium Citri Reticulatae
厚朴	<i>hòu pò</i>	10 g	Cortex Magnoliae Officinalis
炙甘草	<i>zhì gān cǎo</i>	3 g	Radix et Rhizoma Glycyrrhizae Praeparatum Melle
藿香叶	<i>huò xiāng yè</i>	10 g	Herba Agastachis

Copyright Cara O. Frank, 2022

60

Chú Shī Tāng (Dampness- Eliminating Decoction) 除湿汤

连翘	<i>lián qiào</i>	10 g	Fructus Forsythiae
滑石	<i>huá shí</i>	10 g	Talcum
车前子	<i>chē qián zǐ</i>	10 g	Semen Plantaginis
枳壳	<i>zhǐ qiào</i>	10 g	Fructus Aurantii
黄连	<i>huáng lián</i>	10 g	Rhizoma Coptidis
黄芩	<i>huáng qín</i>	10 g	Radix Scutellariae
木通	<i>mù tōng</i>	10 g	Caulis Akebiae
甘草	<i>gān cǎo</i>	10 g	Herba Schizonepetae
陈皮	<i>chén pí</i>	10 g	Pericarpium Citri Reticulatae
荆芥	<i>jīng jiè</i>	10 g	Herba Schizonepetae
茯苓	<i>fú líng</i>	10 g	Poria
防风	<i>fáng fēng</i>	10 g	Radix Saposhnikoviae

Copyright Cara O. Frank, 2022

61

Modified Sì Wù Tāng (四物汤, four substance decoction)

当归	<i>dāng guī</i>	10 g	Radix Angelicae Sinensis
川芎	<i>chuān xiōng</i>	10 g	Rhizoma Chuanxiong
白芍	<i>bái sháo</i>	10 g	Radix Paeoniae Alba
熟地黄	<i>shú dì huáng</i>	10 g	Radix Rehmanniae Praeparata
白僵蚕	<i>bái jiāng cān</i>	10 g	Bombyx Batryticatus
白蒺藜	<i>bái jí lí</i>	10 g	Fructus Tribuli
荆芥	<i>jīng jiè</i>	6 g	Herba Schizonepetae
防风	<i>fáng fēng</i>	6 g	Radix Saposhnikoviae

Copyright Cara O. Frank, 2022

62

Modified *Shēn Líng Bái Zhú Sǎn*/Ginseng, Poria and Atractylodes Macrocephalae Powder

党参	<i>dǎng shēn</i>	10 g	Radix Codonopsis
炒白术	<i>Chǎo bái zhú</i>	15 g	Rhizoma Atractylodis Macrocephalae (prepared)
茯苓	<i>fú líng</i>	10 g	Poria
炙甘草	<i>gān cǎo</i>	6 g	Herba Schizonepetae
山药	<i>shān yào</i>	10 g	Rhizoma Dioscoreae
桔梗	<i>jié gěng</i>	10 g	Radix Platycodonis
白扁豆	<i>bái biǎn dòu</i>	10 g	Semen Lablab Album
莲子肉	<i>lián zǐ ròu</i>	10 g	Semen Nelumbinis
薏苡仁	<i>yì yǐ rén</i>	10 g	Semen Coicis
陈皮	<i>chén pí</i>	10 g	Pericarpium Citri Reticulatae

Copyright Cara O. Frank, 2022

63

Modified *Bǔ Zhōng Yì Qì Tāng* (Center-Supplementing and Qi-Boosting Decoction)

党参	<i>dǎng shēn</i>	15g	Radix Codonopsis
黄芪	<i>huáng qí</i>	15g	Radix Astragali
白术	<i>bái zhú</i>	10g	Rhizoma Atractylodis Macrocephalae
柴胡	<i>chái hú</i>	6g	Radix Bupleuri
当归	<i>dāng guī</i>	6g	Radix Angelicae Sinensis
陈皮	<i>chén pí</i>	6g	Pericarpium Citri Reticulatae
苦参	<i>kǔ shēn</i>	6g	Radix Sophorae Flavescentis
蛇床子	<i>shé chuáng zǐ</i>	6g	Fructus Cnidii
白鲜皮	<i>bái xiān pí</i>	10g	Cortex Dictamni
地肤子	<i>dì fū zǐ</i>	10g	Fructus Kochiae
升麻	<i>shēng má</i>	6g	Rhizoma Cimicifugae
甘草	<i>gān cǎo</i>	3g	Radix et Rhizoma Glycyrrhizae

Copyright Cara O. Frank, 2022

64

◦ **Chinese Patent Drugs**

◦ *Chuān Xīn Lián Tablets* (穿心莲片, Herba Andrographis Tablets), 1-2 tablets , three times a day, applicable to pattern of externally contracted wind-heat.

◦ *Shuāng Huáng Lián Oral Drink* (双黄连口服液, Flos Lonicerae Japonicae and Rhizoma Coptidis Oral Drink), 30 ml , three times a day.

Patent Medicine


Copyright Cara O. Frank 2022

65

Blunt Trauma to the eyeball

◦ 外伤目络证
traumatic injury to the eye collateral

◦ [wài shāng mù luò zhèng]



Copyright Cara O. Frank 2022

66

Ocular contusion

a non-perforated wound resulting from trauma with a blunt object.

Most cases of black eyes are merely a cosmetic concern.

This condition usually results from trauma by a ball, fist, wooden stick, leather, stone or metal shards.

Other causes include:

- high liquid pressure and gas,
- head trauma causing injury
- contusion that may injure the eyeball.

Copyright Cara O. Frank, 2022

67

Complications

If the globe is traumatized there can be more serious complications including:

hemorrhage in the chamber,

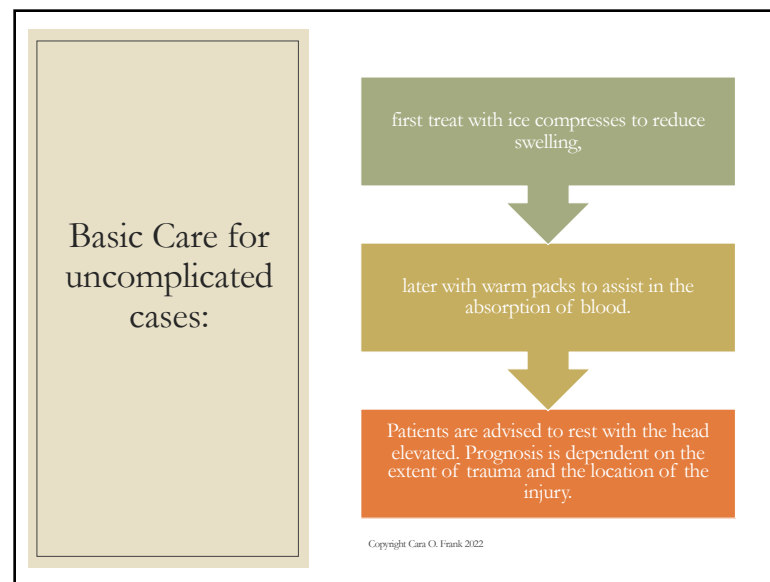
lens dislocation,

retinal hemorrhage, edema or detachment,

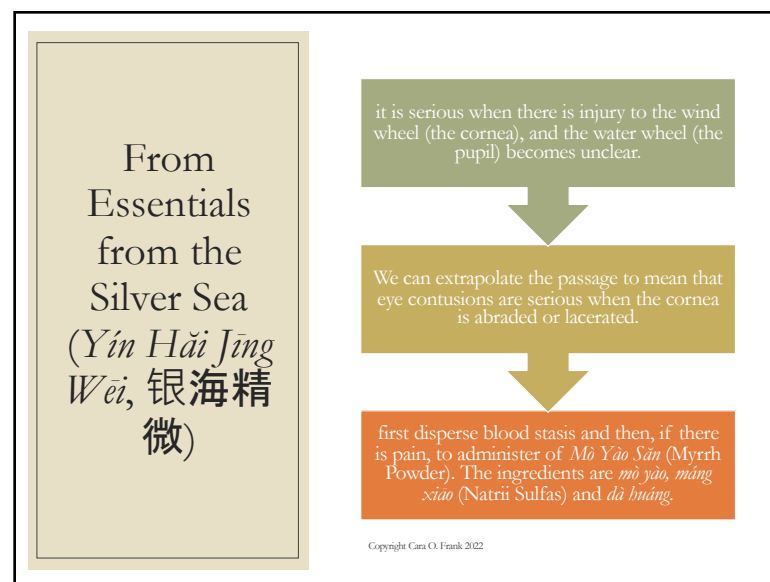
laceration of the iris, cataract formation and late-onset glaucoma.¹

Copyright Cara O. Frank, 2022

68



69



70

TCM Main
Etiology


blunt trauma to the
eyeball injures the qi and
blood

damaging the eye tissue
and causing damage to
the collaterals with blood
spillage, blood stasis and
qi stagnation.

Copyright Cara O. Frank 2022

71

Patterns: only two



Copyright Cara O. Frank 2022

72

Pattern Differentiation

Many channels travel through the eye as well as the deep and minute channels inside the lens, qi and blood can infiltrate the entire eye.

Trauma from a foreign object, damages qi, blood, tissues and collaterals that causes blood spillage.

depending on the location of trauma
There will be different clinical manifestations:

- diagnosis should be based on the location of bleeding.

Copyright Cara O. Frank 2022

73

Case study from my book

Male, age 40. Initial Visit: February 25th, 2009. Patient was hospitalized on the same day.

Chief Complaint: Pain, photophobia and tearing in the left eye along with decreased vision for one hour.


History: One hour prior to treatment the patient suffered a trauma to the left eye with a badminton ball, causing him to develop symptoms of photophobia, pain, tearing and decreased vision. Friends accompanied the patient directly to the hospital.

Signs and Symptoms: Photophobia, pain, tearing and blurred vision in the left eye.

Past History: The patient had no history of contagious disease, other internal organ conditions, use of medicine or food allergies.

Copyright Cara O. Frank 2022

74



Ophthalmologic Examination:

- The eye examination showed visual acuity of the right eye at 1.0 and the left eye at 0.3. No abnormalities were detected in the right eye on the external part of the eyeball or the fundus. The left eyelid was swollen with a dusty discoloration at the posterior wall of the cornea with kp (+) and Tyn (+). There was bleeding with a bright red color covering half of the anterior chamber leaving the rest unclear. Ultrasound of the eye revealed slight cloudiness inside the vitreum with no retina detachment.
- Physical Exam normal

Copyright Cara O. Frank, 2022

75

General Triage Strategy from *Yin Hai Jing Wei*

01 first control bleeding,	02 invigorate blood	03 reduce swelling.
----------------------------------	---------------------------	---------------------------

Copyright Cara O. Frank, 2022

76

Blunt trauma to the collaterals
Early Stage: Modified *Shí Huī Sǎn* (Ten
Charred Substances Powder)

大蓟	<i>dà jì</i>	15g	Herba Cirsii Japonici
大蓟	<i>xiào jì</i>	15g	Herba Cirsii
荷叶	<i>hé yè</i>	12g	Folium Nelumbinis
侧柏叶	<i>cè bǎi yè</i>	10g	Cacumen Platycladi
白茅根	<i>bái máo gēn</i>	10g	Rhizoma Imperatae
茜草	<i>qiān cǎo</i>	10g	Radix et Rhizoma Rubiae
大黄	<i>dà huáng</i>	10g	Radix et Rhizoma Rhei
山梔	<i>shān zhī</i>	10g	Fructus Gardeniae
牡丹皮	<i>mǔ dān pí</i>	10g	Cortex Moutan
棕榈皮	<i>zōng lǚ pí</i>	10g	Petiolus Trachycarpi

Copyright Cara O. Frank, 2022

77

Other treatment

Chinese Patent Medicine

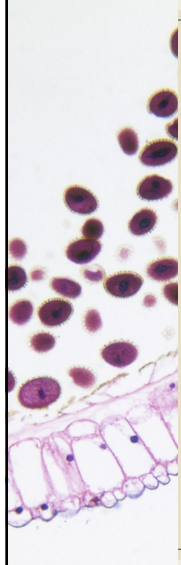
- *Yún Nán Bái Yào Jiāo Náng* (Yunnan Baiyao Capsules): two capsules per dose, taken orally, three times per day.

Special Instructions

- The patient should lay in a supine position with the head elevated at 30 degrees, with both eyes wrapped to prevent movement.

Copyright Cara O. Frank, 2022

78



Follow Up

- After two days of treatment, the symptoms of photophobia, pain and tearing greatly improved. Examination revealed the posterior wall of the cornea with Kp (-) and Tyn (-), and visual acuity had improved to 0.6. The bleeding in the anterior chamber was partially absorbed.
- The color of the blood had turned from bright red to dark red, indicating that no fresh bleeding occurred and the initial bleeding had turned to blood stasis.
- Therefore, medicinals for invigorating blood and transforming stasis were added to the formula.

Copyright Cara O. Frank, 2022

79

Principles: Cool the blood, stop the bleeding, invigorate the blood and transform stasis

Formula: *Shí Huī Sǎn* (Ten Charred Substances Powder) plus *Sì Wú Tāng* (Four Substances Decoction)
[十灰散合四物汤]

大蓟	dà jī	15g	Herba Cirsii Japonici
小蓟	xiǎo jī	15g	Herba Cirsii
荷叶	hé yè	12g	Folium Nelumbinis
侧柏叶	cè bǎi yè	10g	Cacumen Platycladi
白茅根	bái máo gēng	10g	Rhizoma Imperatae
茜草	qiàn cǎo	10g	Radix et Rhizoma Rubiae
大黄	dà huáng	3g	Radix et Rhizoma Rhei
山梔	shān zhī	10g	Fructus Gardeniae
牡丹皮	mǔ dān pí	10g	Cortex Moutan
棕榈皮	zōng lǚ pí	10g	Petiolus Trachycarpi
生地黄	shēng dì huáng	10g	Radix Rehmanniae
当归	dāng guī	10g	Radix Angelicae Sinensis
赤芍	chì sháo	9g	Radix Paeoniae Rubra
川芎	chuān xiōng	9g	Rhizoma Chuanxiong

Copyright Cara O. Frank, 2022

80

Topical care

Apply a compress made of pounded fresh *shēng dì huáng*, *sāng bǎi pí* (Cortex Mori), *cōng bái* (Bulbus Allii Fistulosi), *dài yè* (Folium Artemisiae Argyi) or turnips.

The patient must rest and avoid foods that engender wind and stir the blood.

The prognosis is good for acute injuries and poor if a “white shade develops”, which suggests the eye trauma has caused a nebula to form, which will lead to blindness.

Copyright Cara O. Frank 2022

81

桃仁	<i>táo rén</i>	12g	Semen Persicae
红花	<i>hóng huā</i>	12g	Flos Carthami
当归	<i>dāng guī</i>	12g	Radix Angelicae Sinensis
生地黄	<i>shēng dì huáng</i>	10g	Radix Rehmanniae
赤芍	<i>chì sháo</i>	10g	Radix Paeoniae Rubra
川芎	<i>chuān xiōng</i>	6g	Rhizoma Chuanxiong
桔梗	<i>jié gěng</i>	3g	Radix Platycodonis
牛膝	<i>niú xī</i>	10g	Radix Achyranthidis Bidentatae
柴胡	<i>chái hú</i>	6g	Radix Bupleuri
枳壳	<i>zhǐ qiào</i>	6g	Fructus Aurantii
炙甘草	<i>zhì gān cǎo</i>	3g	Radix et Rhizoma Glycyrrhizae Praeparata cum Melle
木贼草	<i>mù zéi cǎo</i>	12g	Herba Equiseti Hiemalis
菊花	<i>jiú huā</i>	9g	Flos Chrysanthemi
蝉蜕	<i>chán tuì</i>	6g	Periostracum Cicadae

Copyright Cara O. Frank 2022

Sub-Acute: 7 days: Qi Stagnation, Blood Stasis

◦ **Formula:**
Modified *Xuè Fǔ Zhú Yú Tāng*
(Blood Mansion Stasis-Expelling Decoction)

◦ [血府逐瘀汤加減]

82

Ocular
swelling;
Blood Stasis,
Qi
Stagnation

Modified
*Xuè Fǔ Zhú
Yú Tāng*
(Blood
Mansion
Stasis-
Expelling
Decoction)

桃仁	<i>táo rén</i>	12g	Semen Persicae
红花	<i>hóng huā</i>	12g	Flos Carthami
当归	<i>dāng guī</i>	12g	Radix Angelicae Sinensis
生地	<i>shēng dì huáng</i>	10g	Radix Rehmanniae
黄芩	<i>chì sháo</i>	10g	Radix Paeoniae Rubra
赤芍	<i>chūn xiōng</i>	6g	Rhizoma Chuanxiong
川芎	<i>jié gāng</i>	3g	Radix Platycodonis
桔梗	<i>niú xī</i>	10g	Radix Achyranthis Bidentatae
牛膝	<i>chái hú</i>	6g	Radix Bupleuri
柴胡	<i>zhī qiào</i>	6g	Fructus Aurantii
枳壳	<i>āi gān cǎo</i>	3g	Radix et Rhizoma Glycyrrhizae Praeparata cum Melle
炙甘草	茯苓	<i>fú líng</i>	15g Poria
泽泻	<i>zé xiè</i>	12g	Rhizoma Alismatis
车前子	<i>chē qián zǐ</i>	12g	Semen Plantaginis
子			

Copyright Cara O. Frank, 2022

83

<p>Formula: <i>Qū Yū Tāng</i> (Stasis- Dispelling Decoction) [祛瘀汤]</p>	当归	<i>dāng guī</i>	12g	Radix Angelicae Sinensis
	赤芍	<i>chì sháo</i>	12g	Radix Paeoniae Rubra
	桃仁	<i>táo rén</i>	9g	Semen Persicae
	泽兰	<i>zé lán</i>	9g	Herba Lycopi
	丹参	<i>dān shēn</i>	15g	Radix et Rhizoma Salviae Miltiorrhizae
	川芎	<i>chūn xiōng</i>	6g	Rhizoma Chuanxiong
	郁金	<i>yù jīn</i>	12g	Radix Curcumae
	生地	<i>shēng dì</i>	12g	Radix Rehmanniae
	旱莲草	<i>hàn lián cǎo</i>	12g	Herba Ecliptae
	仙鹤草	<i>xiān hè cǎo</i>	12g	Herba Agrimoniae

Copyright Cara O. Frank, 2022

84

